

An external check for disease and health of hatchery-produced sea cucumbers

Steven Purcell¹ and Igor Eeckhaut²

Abstract

Sea cucumber diseases that arise in the hatchery can cripple production and undermine restocking programmes. A rapid protocol for the external examination of juvenile sea cucumbers was developed in order to screen for disease and poor health. After selecting a random sample of juveniles from the entire group, each individual is examined for one minute under low-power microscopy. Six external criteria are checked, including abnormalities of the mouth, anus, papillae, body colour, and signs of excess mucus, unhealed lesions, parasites and macroassociates. If more than 5% of screened animals were “unhealthy” or more than 2% were “diseased”, then the whole group from which the sample was derived should be considered unfit for grow-out or restocking. In such cases, the handling and environmental conditions in the hatchery should be improved and the entire group quarantined and treated. The protocol sets a standardised procedure for checking large numbers of juveniles for many infectious diseases, and is a starting point for further development of standardised protocols.

Introduction

Production of hatchery-reared sea cucumbers has gained global interest, and is underway in Australia, China, Ecuador, Kiribati, Madagascar, Malaysia, New Caledonia and Vietnam. Regardless of whether juveniles are to be used for restocking, stock enhancement or land-based grow-out, diseases can arise in the hatchery and cripple production. Identifying diseases in the hatchery is a precondition for their treatment and a prerequisite for releasing juveniles into the wild. Until recently, however, little was known about sea cucumber diseases.

Diseases can be biomolecular (e.g. hereditary), induced by pathogens, or arise from abiotic factors (Kinne 1980). The United Nations-FAO funded workshop in China (October 2003), “Advances in Sea Cucumber Aquaculture and Management”, improved the collective knowledge of biotic diseases and parasites affecting sea cucumbers. Wang et al. (2004) reported that various pathogens, including bacteria, fungi and other parasites, could affect *Apostichopus japonicus* larvae and juveniles in culture conditions. Clinical signs of infections include lesions starting around the mouth or anus, whitish ulcerations on the skin or papillae, excessive mucus on the body, skin discolouration, and changes in behaviour and appearance (e.g. the infected animals can become thin, weak and sluggish). Eeckhaut et al. (2004) provided a list of bacteria, protozoans and metazoans (e.g. flatworms, gastropods and crustacean parasites) that can potentially cause disease in sea cucumbers. They also

reported a contagious bacterial disease of *Holothuria scabra* that begins as a white lesion close to the anus, followed by a lesion that progresses quickly over the body. Microscopy and biomolecular techniques have proved instrumental in identifying the bacterial species associated with that disease, called “skin ulceration disease” (Becker et al. 2004). Symptoms of many of the diseases reported by Wang et al. (2004) and Eeckhaut et al. (2004) can be seen externally by low-power microscopy so it should be possible to screen juveniles for visible symptoms of diseases prior to transfer to grow-out ponds or into the wild.

Aside from true biotic diseases, some sea cucumber illnesses can be viral, chemical or from poor culture environment. For example, excess aeration or inappropriate temperatures cause illness and death in sea cucumber larvae (Hamel et al. 2001; Wang et al. 2004). In New Caledonia, copper wire placed in tanks was sufficient to kill juveniles within days (S. Purcell, unpubl. data). Illnesses may be subtle with no lesion or malformation. Instead, the animals become unhealthy and the symptoms could include sluggishness or change in body colour. Illness from chemical contamination could reduce feeding in juveniles and make them more prone to predation when they are released into the wild.

The impacts of releasing diseased or unhealthy juveniles into the wild can be indirect or direct. First, contagious diseases from hatchery-reared sea cucumbers can spread to native stocks, competitors or predators. For example, some bacterial strains can be infectious to other invertebrates

1. The WorldFish Center, c/o Secretariat of the Pacific Community, BP D5, 98848 Noumea Cedex, New Caledonia.
Email: s.purcell@cgjar.org

2. Laboratoire de Biologie Marine, Université de Mons-Hainaut, 6 ave. du Champs de Mars, B-7000 Mons, Belgium

and to fish (see Becker et al. 2004). Second, the reduced fitness of released animals can cause unexplained mortality, if they die soon after release, or can make them more prone to predation if their natural mechanisms to avoid predation (e.g. chemical deterrents, burrowing behaviour or camouflage) are diminished.

A screening procedure is needed to reduce the risk of releasing diseased animals into the wild. Here we present a protocol for the rapid checking of sea cucumber juveniles under a dissecting microscope, guidelines for determining whether juveniles are fit for release, and some specific criteria for disease screening of *Holothuria scabra*.

Disease and health check

Pre-screening preparations

In order for disease screening to reflect the status of juveniles in the group, random sampling of juveniles from the entire pool of juveniles at the hatchery is essential. As a guide, the number of juveniles in the sample should be no less than the square root of the total number of juveniles in the batch.

1. Randomly sample a group from the batch of cultured juveniles.
2. Place each live juvenile in a Petri dish with seawater and examine under a dissecting microscope (Fig. 1a).
3. Following the procedures below, and verifying each point in the proceeding checklist for each animal, score any abnormalities on a proforma in two categories: “unhealthy” or “diseased”. Unhealthy juveniles are those with symptoms

of stress or mishandling, whereas “diseased” juveniles show symptoms of infection by pathogens.

Screening protocol

The following points relate to various indicators of health and disease. Checking each point individually, the complete screening of all points should take around 1 minute per juvenile.

- I. Confirm that the skin and papillae colouration is “normal” and healthy. *H. scabra* juveniles from the Pacific can be black or display mottled colouration of greenish beige, brown and grey, with black speckling (Fig. 1b). The papillae can appear wart-like, which is normal (Figs. 2a, b, c). There should be some thinly scattered podia (tube feet) on the dorsal surface, and many more ventrally. The podia will appear as a dark spot when retracted. Tube feet can be coloured dark yellow, black or grey-brown, and are arranged irregularly. The ventral surface should be generally more whitish or cream coloured (Fig. 2b). Juvenile sea cucumbers that are handled and then placed back into seawater may bloat with water. This is a normal sign of mild stress but the bloating should subside within one hour. Juveniles with body colour that is unusually pale should be scored as “diseased” for precautionary reasons.
- II. Check any malformation, or abnormal retraction, of the mouth or the area around the anus. Refer to taxonomic literature on the normal arrangement of papillae (e.g. Conand 1998). The mouth and oral tentacles, if visible, should be normal in colour; in *H. scabra*, these should be

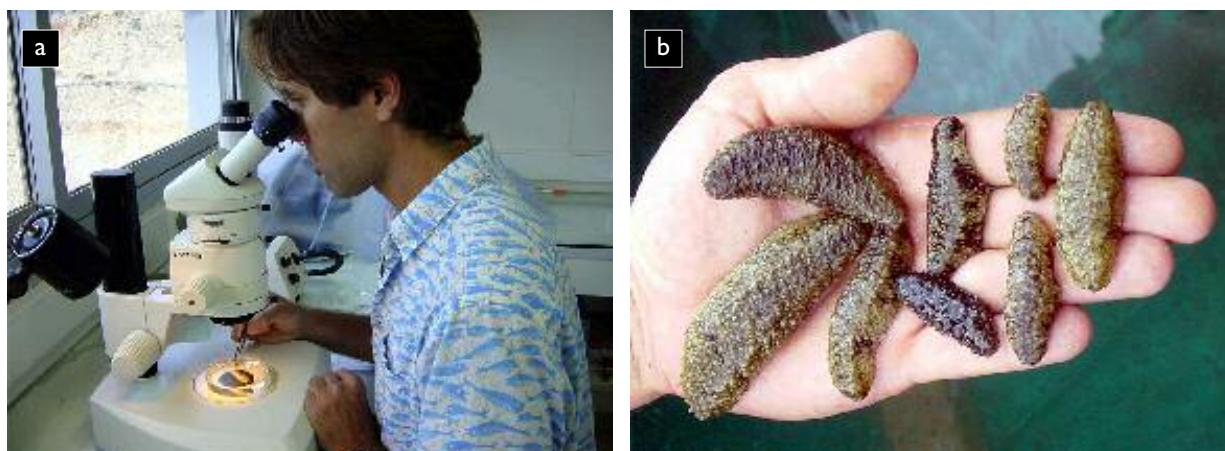

Figure 1.

- (a) Checking juveniles for signs of disease using a low-power (dissecting) microscope.
 (b) Varied colours and colour patterns of healthy juvenile sandfish *Holothuria scabra* from the WorldFish hatchery in New Caledonia (approx. 2–20 g).

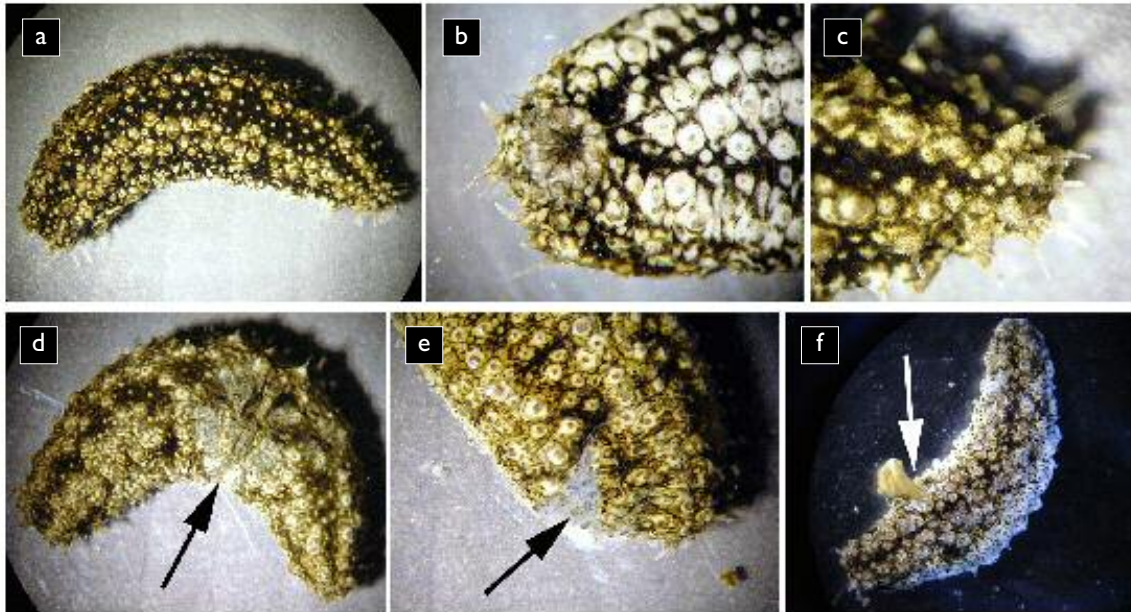


Figure 2.

- (a) A healthy juvenile sandfish (approx. 1 g or 20 mm) under low-power microscope.
 (b) Ventral surface and mouth of healthy juvenile sandfish.
 (c) Dorsal surface and anus of healthy juvenile sandfish.
 (d) Juvenile sandfish with healed lesion on the middle of the dorsal surface, indicated by arrow.
 (e) Open lesion, exposing white muscle tissue (indicated by arrow), near anus of juvenile sandfish.
 (f) Extreme injury in juvenile sandfish with part of intestine protruding out of open lesion on dorsal surface, indicated by arrow.

yellowish-grey (Fig. 2b). Juvenile sandfish should not have any white spots near the anus (Fig. 2c). Score as “diseased” if abnormal.

- III. Juveniles sometimes feel slightly slimy. However, juveniles with excessive mucus on the skin should be scored as “unhealthy”.
- IV. Check the entire body (including buccal region and anus) for any fungal or bacterial infections. Juveniles with white spots, whitish fluffy patches or cysts on the body should be scored as “diseased”.
- V. It is not unusual for juveniles in the hatchery to have some scars from handling in the transfer among tanks or outdoor enclosures, so juveniles with healed scars (e.g. Fig. 2d) can be considered healthy. Check the entire body for open lesions (e.g. Fig. 2e and 2f). Score as “unhealthy” if the skin is damaged and not closed.
- VI. Confirm that juveniles are not infested by macroassociates such as polychaetes, marine nematodes (roundworms), crabs, eulimid gastropods or copepods. A few copepods can be present on healthy individuals but a density of more than 5 copepods or nematodes on a small juvenile (1–5 cm long) is abnormal. Score as “unhealthy” if infested.

Checklist for each individual

A table including cells for each of the points in the *Screening Protocol* should be used to record the date of screening, number of juveniles and scores for each point. Score each point for each juvenile (e.g. with a tick for okay and a cross for “unhealthy” or “diseased”) as a record that each point was examined. Individuals with one “unhealthy” or “diseased” score in the following checklist have failed the screening.

Disease

- Skin and papillae colouration is “normal” and healthy.
- No white spots, malformation or abnormal retraction of the mouth or anus.
- Oral tentacles, if visible, are yellowish-grey.
- Ventral surface should be generally more whitish or cream-coloured.
- No fungal or bacterial infections, involving white spots or fluffy patches on the body.

Health

- No prominent layer of mucus on the skin.
- Body with no open lesions or scars with un-

- sealed epidermis.
- No infestation of macroassociates.

Post screening

Once each juvenile in the sample has been screened and points scored, the final step is to assess the “fitness” of the complete group at the hatchery, based on the screened sample of juveniles, and take actions if the screening indicates unacceptable proportions of unhealthy or diseased juveniles.

1. Determine proportional score of the group. Pass the total group as “fit” if no more than 5% of screened animals were scored as “unhealthy” and if no more than 2% of screened animals were scored as “diseased”. These guidelines permit some occurrence of stressed juveniles, as this may be unavoidable during handling at the hatchery, but places stricter control on potential risks of diseases.
2. If possible, take photos via the microscope of any “unhealthy” or “diseased” juveniles. Preserve any “diseased” juveniles in 100% analytical-grade alcohol and label accordingly. These preserved specimens can be analysed later.
3. If the screening suggests that the group is unhealthy, improve the handling and environmental conditions in the hatchery and allow sufficient time for recovery. If the screening shows an unacceptable proportion of “diseased” juveniles, the entire group should be quarantined and a disease treatment applied. Treatment of disease should start with improving water quality and stocking conditions (e.g. see Battaglione et al. 1999), then consider an application of chemicals, such as a low-dosage of formalin-based products, or antibiotics, such as oxytetracycline at 1–5 ppm. Do not use copper-based disease remedies. Re-screen a further random sample of juveniles no earlier than two weeks after treatment.
4. Do not attempt to release juveniles from groups that have had recent unexplained mortality. The deaths may be due to disease and surviving animals that appear to be healthy could be carriers of disease.

Discussion

This protocol will not provide a definitive or comprehensive certification that sea cucumbers are disease-free because some protozoans and metazoan parasites occur in the digestive tract and coelom and do not manifest clear external symptoms (Eeckhaut et al. 2004). However, the protocol is useful for rapidly checking a large number of juveniles for many infectious diseases, and is a

starting point for further development of standardised protocols.

Hatcheries should not rely on the use of these protocols alone to avoid the transfer of diseased or unhealthy sea cucumbers. Precautions should be taken throughout the culture cycle to reduce the risk of diseases. These precautions include:

- 1) keeping the number and biomass of animals within reasonable limits (Eeckhaut et al. 2004);
- 2) maintaining good water quality and limiting temperature extremes to minimise stress on juveniles;
- 3) handling and transferring juveniles gently to minimise abrasions that break the external mucous layer and epidermis, exposing tissue to infection.

Also, some infections arise when bacteria are at unacceptably high levels and when the sea cucumbers are stressed or wounded. For example, lesions and death of juvenile and adult *H. scabra* occurred in earthen ponds in New Caledonia where dissolved oxygen and temperature could not be controlled.

If disease is found, the infected animals should be quarantined and treated or destroyed. One overarching comment raised by pathologists that we consulted was the need to establish a database of sea cucumber pathogens. In this regard, a study of diseases, and their prevalence, in natural populations of sea cucumbers would be invaluable. An additional need is for a repository of reference material detailing normal histology of healthy sea cucumbers. Accordingly, Pierre Becker (Université de Mons-Hainaut, Belgium) has requested samples of infected individuals so that the infectious agent can be identified by microscopic and/or biomolecular methods. A database of pathogens and resulting diseases will be a valuable tool for progressing a better understanding of diseases of cultured sea cucumbers.

Acknowledgements

We thank J. Bell and W. Nash for their helpful comments on the manuscript. Advice on pathology tests was provided by Mark Crane of the Australian Animal Health Laboratory. Financial support for this work was provided by the Australian Centre for International Agricultural Research (ACIAR) and the three Provinces of New Caledonia. This is WorldFish Center contribution #1752.

References

- Battaglione S.C., Seymour, J.E. and Ramofafia C. 1999. Survival and growth of cultured juvenile

- sea cucumbers, *Holothuria scabra*. Aquaculture 178:293–322.
- Becker P., Gillan D., Lanterbecq D., Jangoux M., Rasolofonirina R., Takotovao J. and Eeckhaut I. 2004. The skin ulceration disease in cultivated juveniles of *Holothuria scabra* (Holothuroidea, Echinodermata). Aquaculture 242:13–30.
- Conand C. 1998. Holothurians. p. 1157–1190. In: Carpenter K.E. and Niem V.H. (eds). The living marine resources of the Western Central Pacific, Volume 2: Cephalopods, crustaceans, holothurians and sharks. FAO Species Identification Guide for Fishery Purposes. FAO, Rome. 1396 p.
- Eeckhaut I., Parmentier E., Becker P., Gomez da Silva S., Jangoux M. 2004. Parasites and biotic diseases in field and cultivated sea cucumbers. p. 311–325. In: Lovatelli A., Conand C. Purcell S., Uthicke S., Hamel J.-F. and Mercier A. (eds). Advances in sea cucumber aquaculture and management. FAO Fisheries Technical Report No. 463, FAO, Rome. 425 p.
- Hamel J.-F., Conand C., Pawson D. and Mercier A. 2001. The sea cucumber *Holothuria scabra* (Holothuroidea: Echinodermata): its biology and exploitation as beche-de-mer. Advances in Marine Biology 41:129–223.
- Kinne O. 1980. Diseases of Marine Animals: General Aspects. p. 13–73. In: O. Kinne (ed). Diseases of Marine Animals. John Wiley & Sons, Chichester, New York.
- Wang, Y.G., Zhang C.Y., Rong X.J., Chen J.J. and Shi C.Y. 2004. Diseases of cultured sea cucumber, *Apostichopus japonicus*, in China. p. 297–310. In: Lovatelli A., Conand C. Purcell S., Uthicke S., Hamel J.-F. and Mercier A. (eds). Advances in sea cucumber aquaculture and management. FAO Fisheries Technical Report No. 463, FAO, Rome. 425 p.

An incidence of parasitic infestation in *Holothuria atra* Jaeger

M.K. Ram Mohan¹ and D.B. James²

The reproductive cycle of the sea cucumber *Holothuria atra* was studied at Tuticorin, on the southeast coast of India (8°45'N, 78°12'E). Specimens were collected from Tuticorin Bay from November 1997 to April 1999. Collected specimens were cut open by making an incision through the anal portion to open up the coelom, exposing the viscera (including gonads) for the purpose of studying the gonadal reproductive stage. During the course of study, two parasitic gastropods were found in the cloacal chamber of one specimen, which was at an indeterminate stage of sexual maturity.

This gastropod, according to Waren (1983), belongs to the genus *Megadenus* sp. The classification is as follows: Class: Gastropoda; Subclass: Prosobranchia; Order: Caenogastropoda; Superfamily: Eulimoidea; Family: Eulimidae; Genus: *Megadenus*.

The parasites, which were noticed during September 1998, were embedded in the wall tissue of the cloacal chamber. The shell breadths of the gastropods were 2.8 mm and 2.2 mm, the smaller one being the male. The sea cucumber weighed 160 g. During the study, a total of 994 specimens were examined, and infestation of parasites in the cloacal chamber was found in only one animal. Hence, it could be assumed that about 0.1% of the population was infested by the above-mentioned parasite.

Jones and James (1970) reported a gastropod parasite, *Stilifer* sp., from the cloacal chamber of *H. atra*. They recovered 13 gastropods from 8 infested specimens, after examining 1359 specimens. The infestation rate was 0.58%. Further studies on the physiological implications of parasitic infestations are required, as effects such as castration could affect and influence the parameters of the sea cucumber population in a particular locality.

References

- Jones S. and James D.B. 1970. On the stiliferid gastropod in the cloacal chamber of *Holothuria atra* Jaeger. Proceedings of the Symposium on Mollusca Organised by CMFRI, Cochin, India. Pt. 3:799–804.
- Ram Mohan M.K. 2001. Annual reproductive cycle of *Holothuria (Halodeima) atra* Jaeger (Holothuroidea: Aspidochirota) at Tuticorin, Southeast coast of India. PhD thesis, Central Institute of Education, Mumbai, India. 111 p.
- Waren A. 1983. A generic version of the family Eulimidae (Gastropoda, Prosobranchia). Supplement 13, Journal of Molluscan Studies. 53–54.

1. Assistant Director, Marine Products Export Development Authority, Veraval-362 269, Gujarat, India
2. Principal Scientist (Retd), No. 37, Sadsivam Mehta Street, Mehta Nagar, Chennai-29, India